



---

## Anterior crossbite and crowding correction with a series of clear aligners: case report

**Peer review status:**

No

**Corresponding Author:**

Dr. Amira Al Habash,  
dentist, Policlinica Identalia - Italy

**Submitting Author:**

Dr. Amira Al Habash,  
dentist, Policlinica Identalia - Italy

**Other Authors:**

Dr. David Raickovic,  
dentist, Policlinica Identalia - Croatia

**Article ID:** WMC005610

**Article Type:** Case Report

**Submitted on:** 18-Mar-2020, 06:16:34 PM GMT **Published on:** 24-Mar-2020, 02:51:34 AM GMT

**Article URL:** [http://www.webmedcentral.com/article\\_view/5610](http://www.webmedcentral.com/article_view/5610)

**Subject Categories:** ORTHODONTICS

**Keywords:** orthodontics, clear aligners, invisalign, dentistry, crossbite, oral medicine

**How to cite the article:** Al Habash A, Raickovic D. Anterior crossbite and crowding correction with a series of clear aligners: case report. WebmedCentral ORTHODONTICS 2020;11(3):WMC005610

**Copyright:** This is an open-access article distributed under the terms of the [Creative Commons Attribution License \(CC-BY\)](#), which permits unrestricted use, distribution, and reproduction in any medium, provided the original author and source are credited.

**Source(s) of Funding:**

The authors declare that they have not received funding.

# Anterior crossbite and crowding correction with a series of clear aligners: case report

**Author(s):** Al Habash A, Raickovic D

## Introduction

Nowadays, there is a growing demand for aesthetic treatment among both adolescents and adults. Indeed, a recent study estimated that 45% of adults are unhappy with their smile and that 20% of these have considered undergoing orthodontic treatment to improve their appearance. Hence, aligner systems must now be able to treat various types of malocclusion, and over recent years, many studies have shown their great efficacy in correcting crowding, crossbite and diastemas, and even complex cases featuring extraction, open-bite, and poor occlusal relationships.

Invisalign is a new technique able to resolve some orthodontic malocclusions without the use of traditional fixed equipment.

The real innovation of the methodology is represented by Clin-Check, a digital three-dimensional simulation that allows clinicians and the patients to see a film on the computer tracking the movements from beginning to end of the dental treatment.

The Aligners, made of transparent thermoplastic polymer, allow a tooth movement of 0,15 to 0,25 mm; they must be worn at least 22 hours a day and have to be replaced every 10 days with the next aligner. The possibility of removing these alignments also allows the patient to control daily oral hygiene.

Some types of movement are favoured by the Attachments forms at the dental composite used in relation to their shape and positioning that determine movements such as intrusion, extrusion, rolling, fluid, torque, up righting of the root. In order to provide masks without defect it is crucial to make impressions with intraoral scan in order to obtain precise study models.

## Case Report

This case report describes an adult male patient with class I subdivision, dental crossbite, and crowding treated successfully with aligners.

A 35 years old patient came to our observation complaining of a relational problem regarding poor

aesthetics of the smile (Figs. 1, 2).

Clinical examination revealed class I subdivision with lower midline deviation towards the left of the upper midline, a severe crowding in the inferior (Fig. 4) dental arch, with the presence of cross bite against the elements 2.2, 3.3 (Figs. 3, 5).

The pre-treatment OPT (Fig. 7) shows the presence of all the permanent teeth with overall good alveolar bone density and good root morphology.

Periodontal biotype and oral hygiene were good (Fig.2)

## Treatment objectives

The treatment objectives were to align the arches, correct the crossbite, centering the lower midline and obtain ideal overbite and overbite. Upper and lower crowding was to be resolved by interproximal reduction.

Additional objectives were to improve facial aesthetic and reduce black buccal corridors during smiles

The buccal segment occlusion and Class I molar relationship was to be maintained with both fixed and removable retainers to maintain the treatment outcomes.

In view of the case history, a non-invasive treatment was chosen that would resolve aesthetic and functional problems. The Patient's desire was to improve the smile, but without going through fixed type traditional orthodontics.

## Treatment progress

The virtual set-up dictated 27 treatment steps for each arch.

To achieve the correction of the crossbite, the plan involved disto-rotation of tooth 3.3 (21.1 degrees D) and proclination of 1.2 (13.1 degrees B) in association with lingual bite ramps put on 1.2, 1.1, 2.1, 2.2.

To achieve lower midline correction, the plan involved IPR on lower teeth and sequential movement towards right side of 4.1, 3.1, 3.2 using spaces of IPR.

In order to align lower frontal teeth, IPR in combination with proclination and then retrusion and intrusion of

lower frontal teeth was done. Tooth 3.2 was inclined (9.9 degrees B)

in the meantime the root was inclined (9.9 degrees L).

In upper arch, element 2.3 was inclined (19.5 degrees M) in order to allow tooth 2.2 to incline buccally (9.9 degrees) and be fully aligned.

Power ridges were used on 1.2, 1.1, 2.1, 2.2 in order to improve the overjet.

The patient was instructed to wear each aligner for 22 h per day and to move on to the next one in the series after 10 days.

At the end of treatment a successful outcome was achieved (Fig. 8). Both upper and lower arches were well aligned with complete correction of crossbite (Fig. 9).

Only the midline was not completely centered, but the patient was satisfied and refused to wear additional aligners.

## Treatment results

Post-treatment records demonstrate satisfactory final results with all objectives achieved, only the lower midline is not completely centred but improved.

Extraoral photos show a good profile, correct incisor exposure during smile and absence of buccal corridors (Fig.9). Intraoral examination reveals the achievement of all planned objectives, crossbite correction and crowding correction (Fig.8). Post-treatment panoramic radiography (Fig.10) showed good root parallelism, no sign of crestal bone height reduction, and no evidence of apical root resorption.

## Summary and conclusions

Use of aligners is an efficacious means of resolving orthodontic issues such as dental cross-bite and crowding within a time-frame comparable to conventional fixed orthodontics, but with excellent aesthetics and oral hygiene.

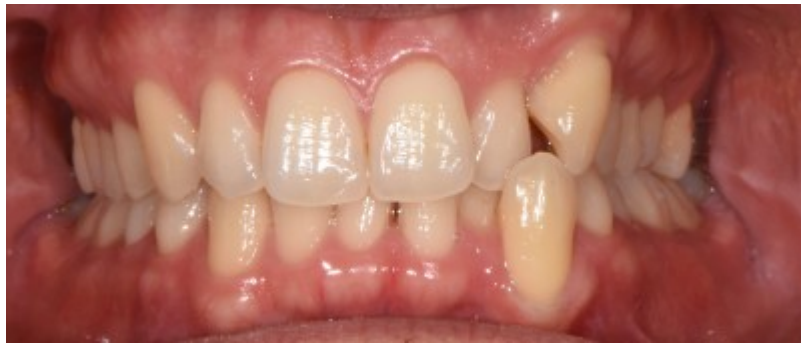## References

- Walton DK, Fields HW, Johnston WM, Rosenstiel SF, Firestone AR, Chirstensen JC. Orthodontic appliance preferences of children and adolescents. *Am J Orthod Dentofac Orthop.* 2010;138(6):698.e1 12.
- Feu D, Catharino F, Duplat CB, Capelli Junior J. Esthetic perception and economic value of orthodontic appliances by lay Brazilian adults. *Dental Press J Orthod.* 2012;17(5):102 14.
- British Orthodontic Society. News release, [www.bos.org.uk/news/NOWYouGovSurvey](http://www.bos.org.uk/news/NOWYouGovSurvey). Accessed 9 Apr 2013.
- Boyd RL, Miller RJ, Vlaskalic V. The Invisalign system in adult orthodontics: mild crowding and space closure cases. *J. Clin. Orthod.* 2000;34(4):04 203.
- Womack WR. Four-premolar extraction treatment with Invisalign. *J Clin Orthod.* 2006;40:493 500.
- HÄnn M, GÄtz G. A premolar extraction case using the Invisalign system. *J Orofac Orthop.* 2006;67:385 94.
- Boyd RL. Complex orthodontic treatment using a new protocol for the Invisalign appliance. *J Clin Orthod.* 2007;41:525 47.
- Boyd RL. Esthetic orthodontic treatment using the Invisalign appliance for moderate to complex malocclusions. *J. Dent. Ed.* 2008;72:948 67.
- Tuncay OC, editor. *The Invisalign system.* 1 ed Quintessence Publishing; 2006.
- Align Technology
- Boyd RL, Oh H, Fallah M, Vlaskalic V. An update on present and future considerations of aligners. *J Calif Dent Assoc.* 2006;34:793 805.
- Nedwed V, Miethke RR. Motivation, acceptance and problema of Invisalign patients. *J Orofac Orthop.* 2005;66:162 173.

## Illustrations

### Illustration 1

Smile before treatment



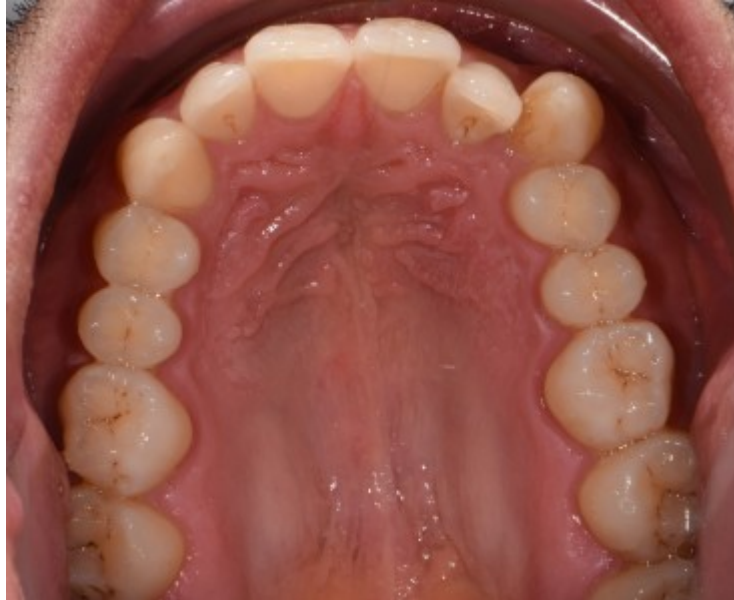### Illustration 2

Frontal view (t0)



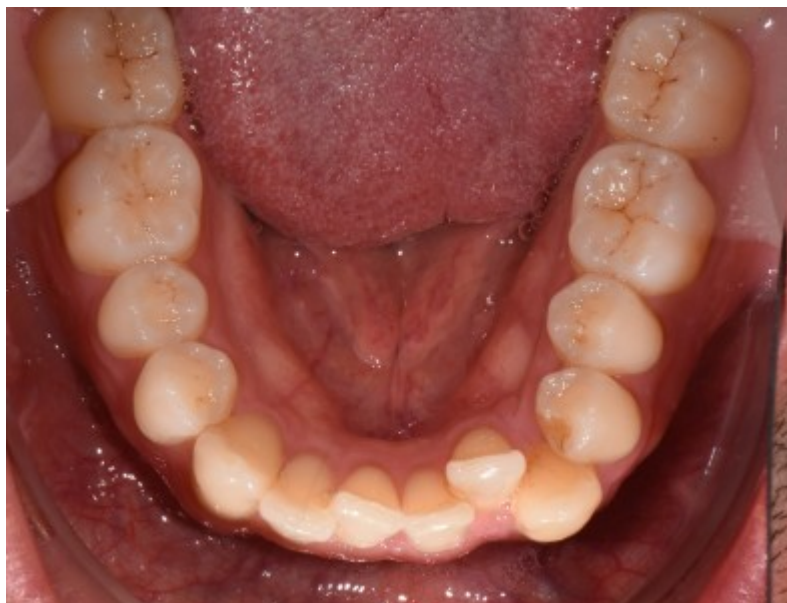### Illustration 3

Occlusal view upper arch (t0)



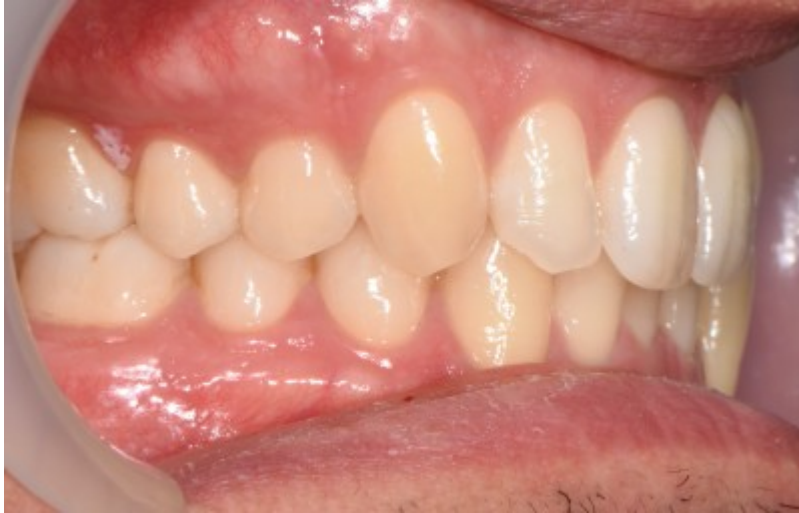### Illustration 4

Occlusal view lower arch (t0)



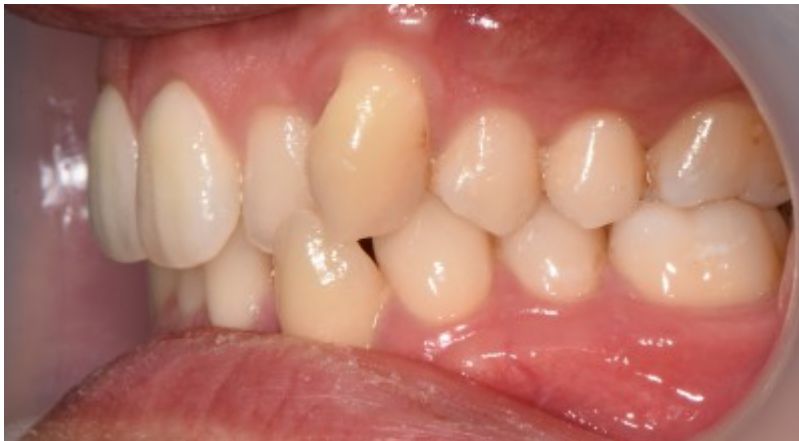## Illustration 5

Lateral view right side



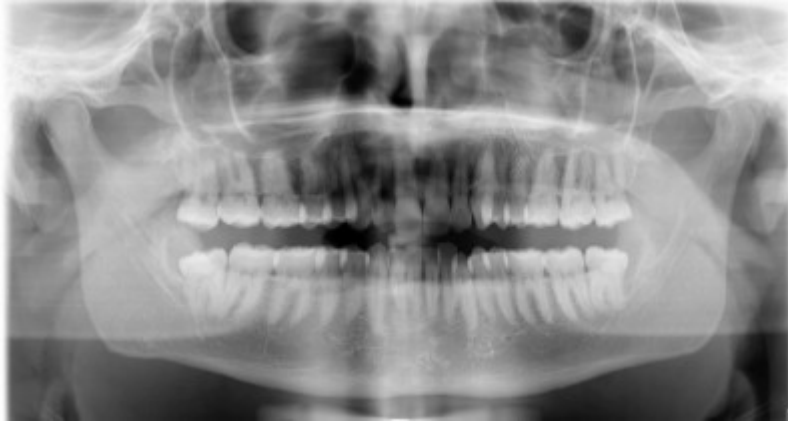
## Illustration 6

Lateral view left side



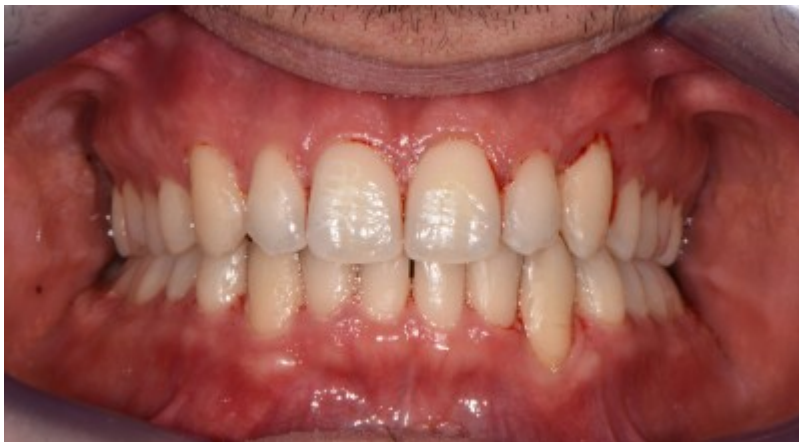## Illustration 7

OPT before treatment



## Illustration 8

Smile after treatment



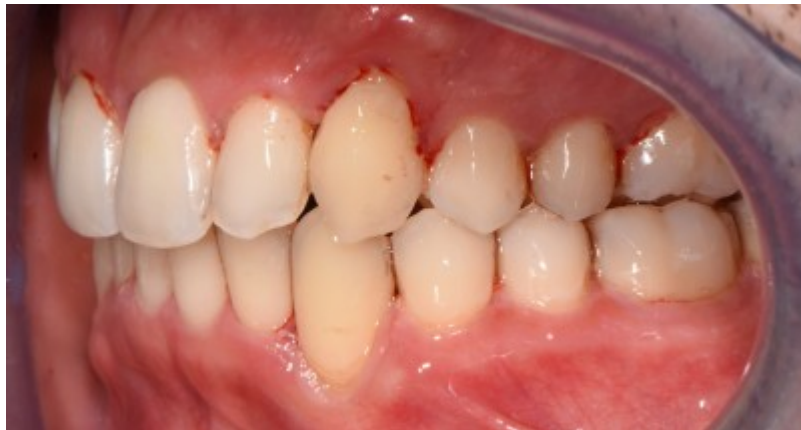## Illustration 9

Extra-oral photo after treatment



## Illustration 10

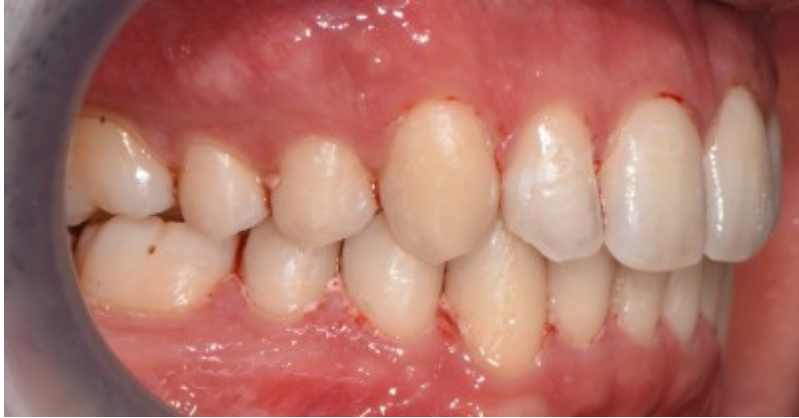Lateral view left side after treatment





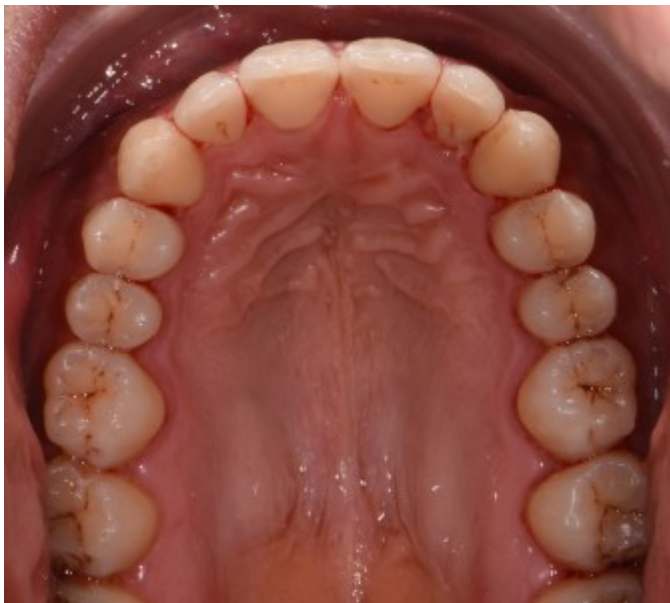## Illustration 11

Lateral view right side after treatment



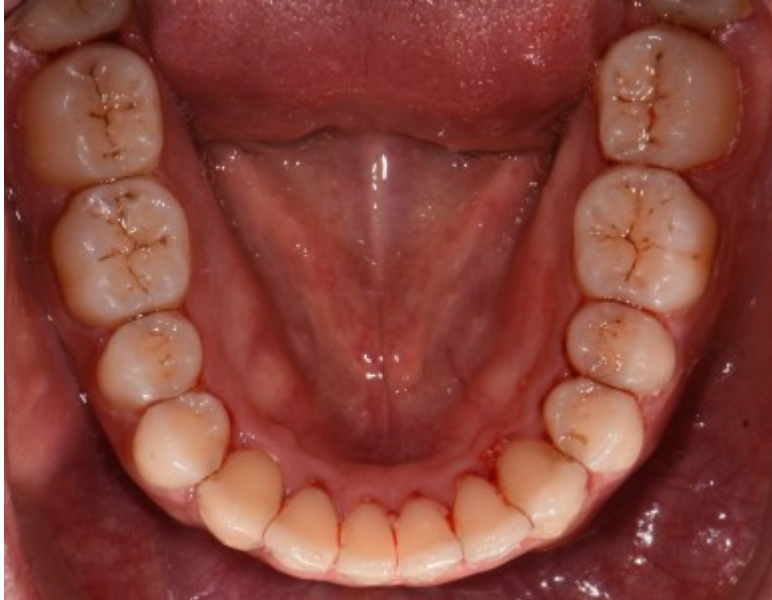## Illustration 12

Occlusal view upper arch after treatment



## Illustration 13

Occlusal view lower arch after treatment



## Illustration 14

OPT after treatment

